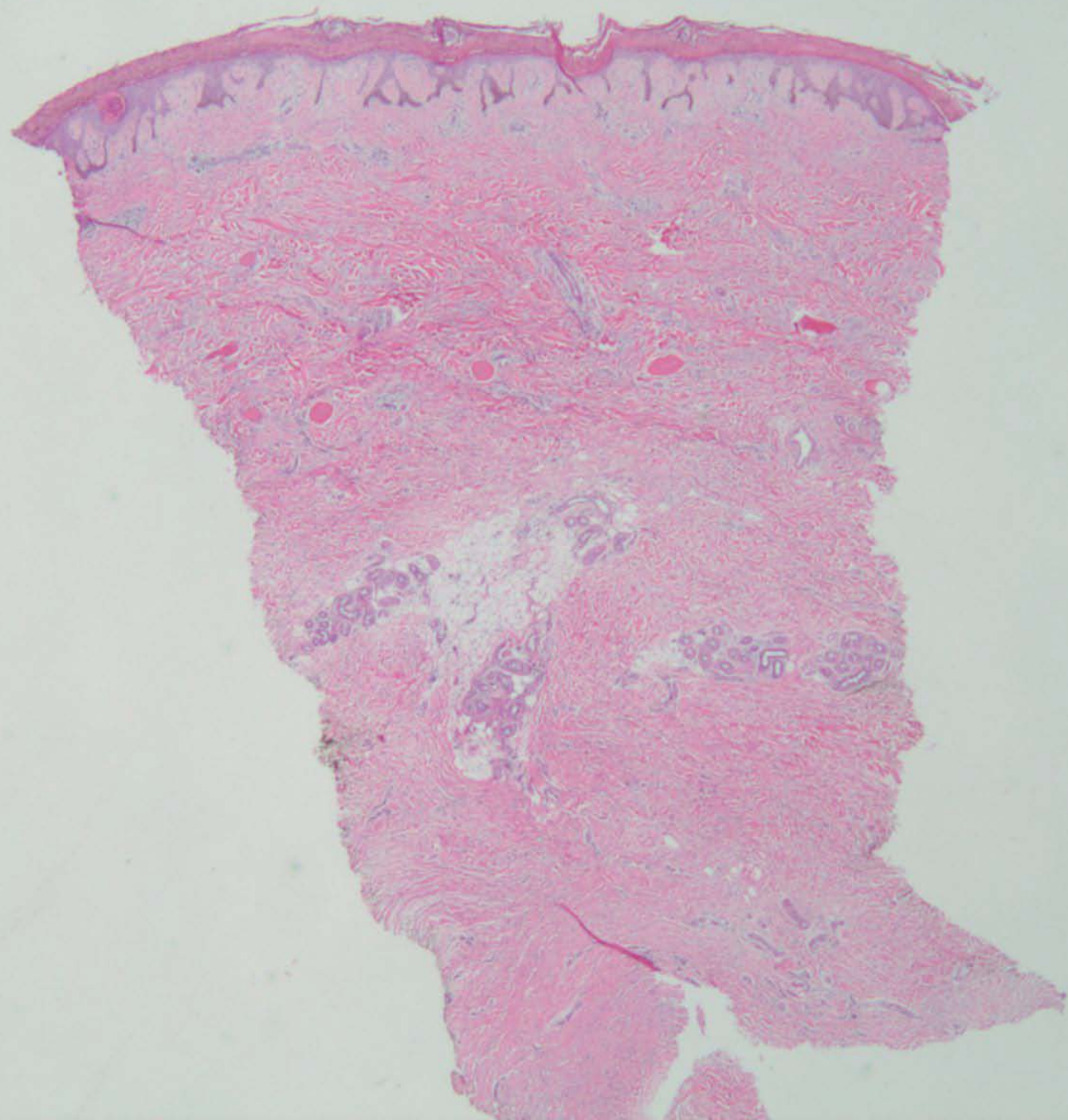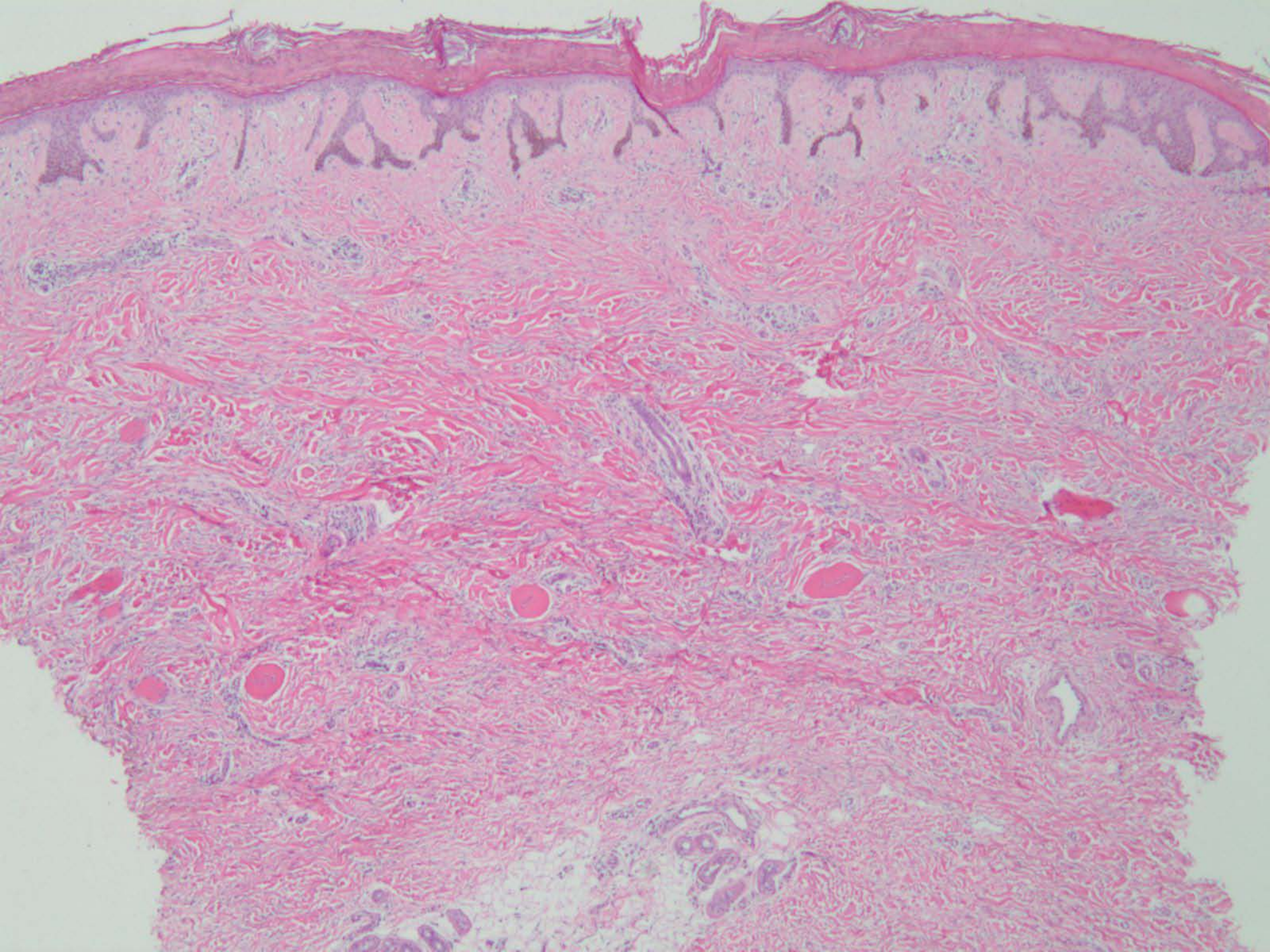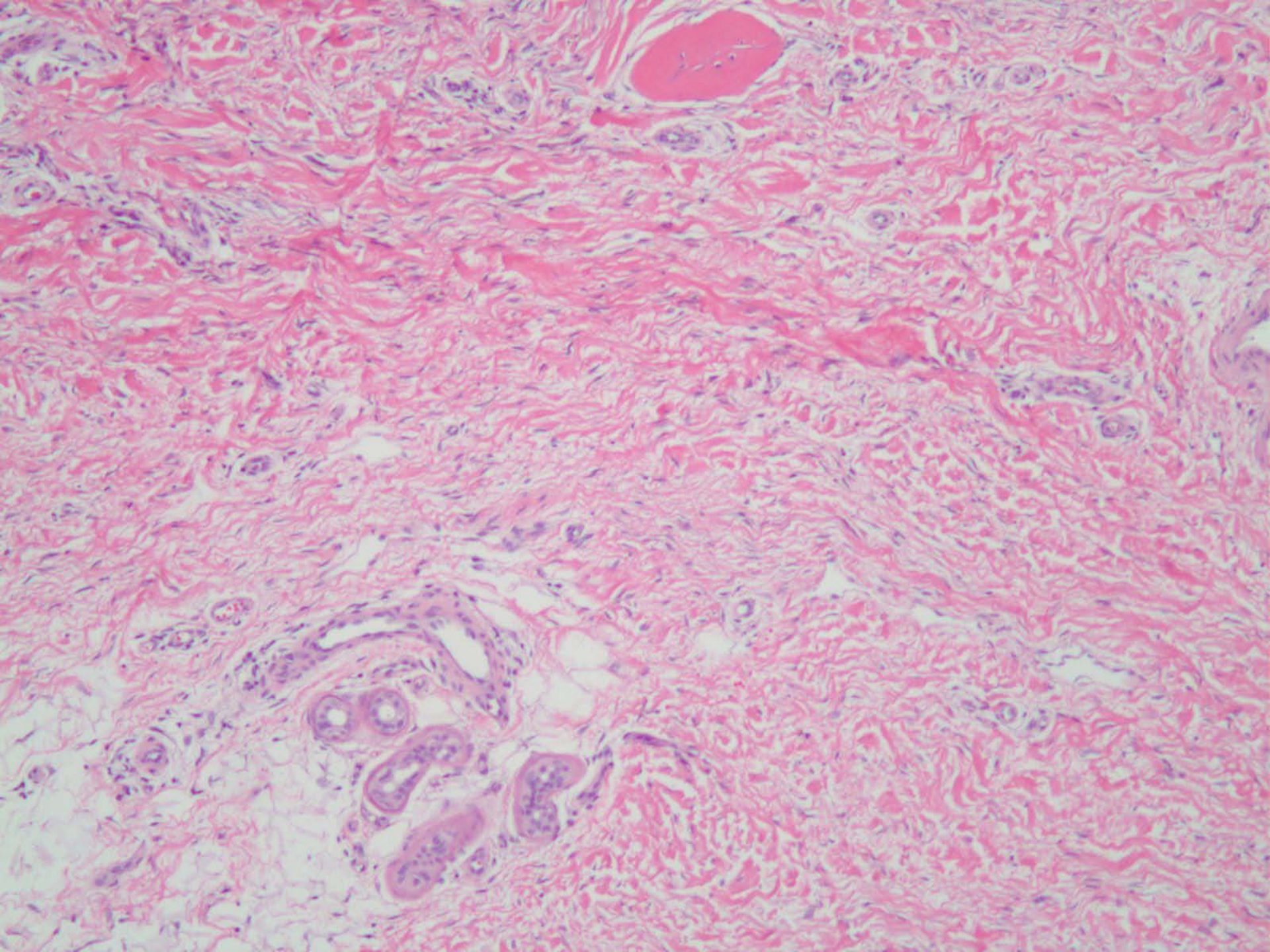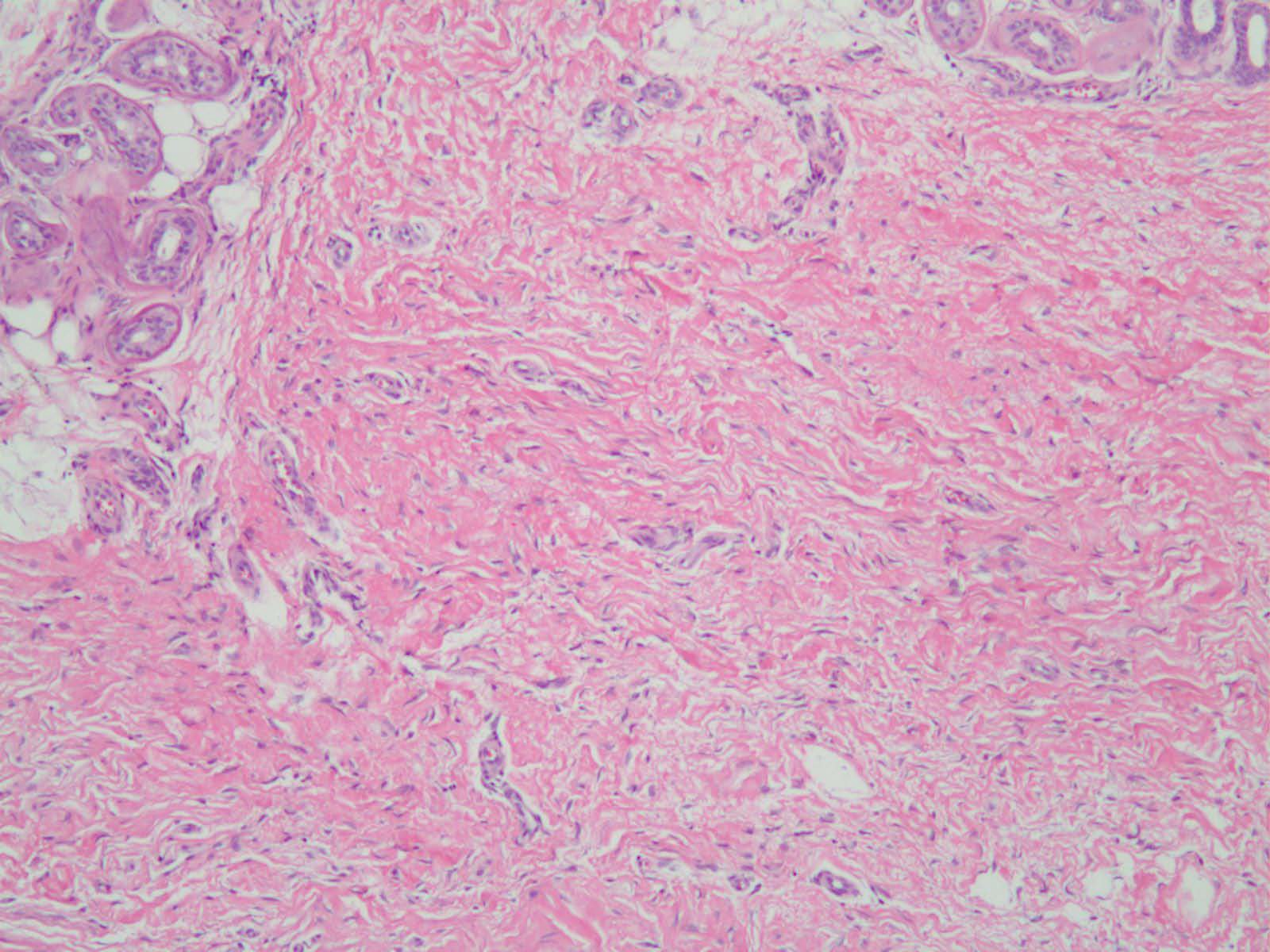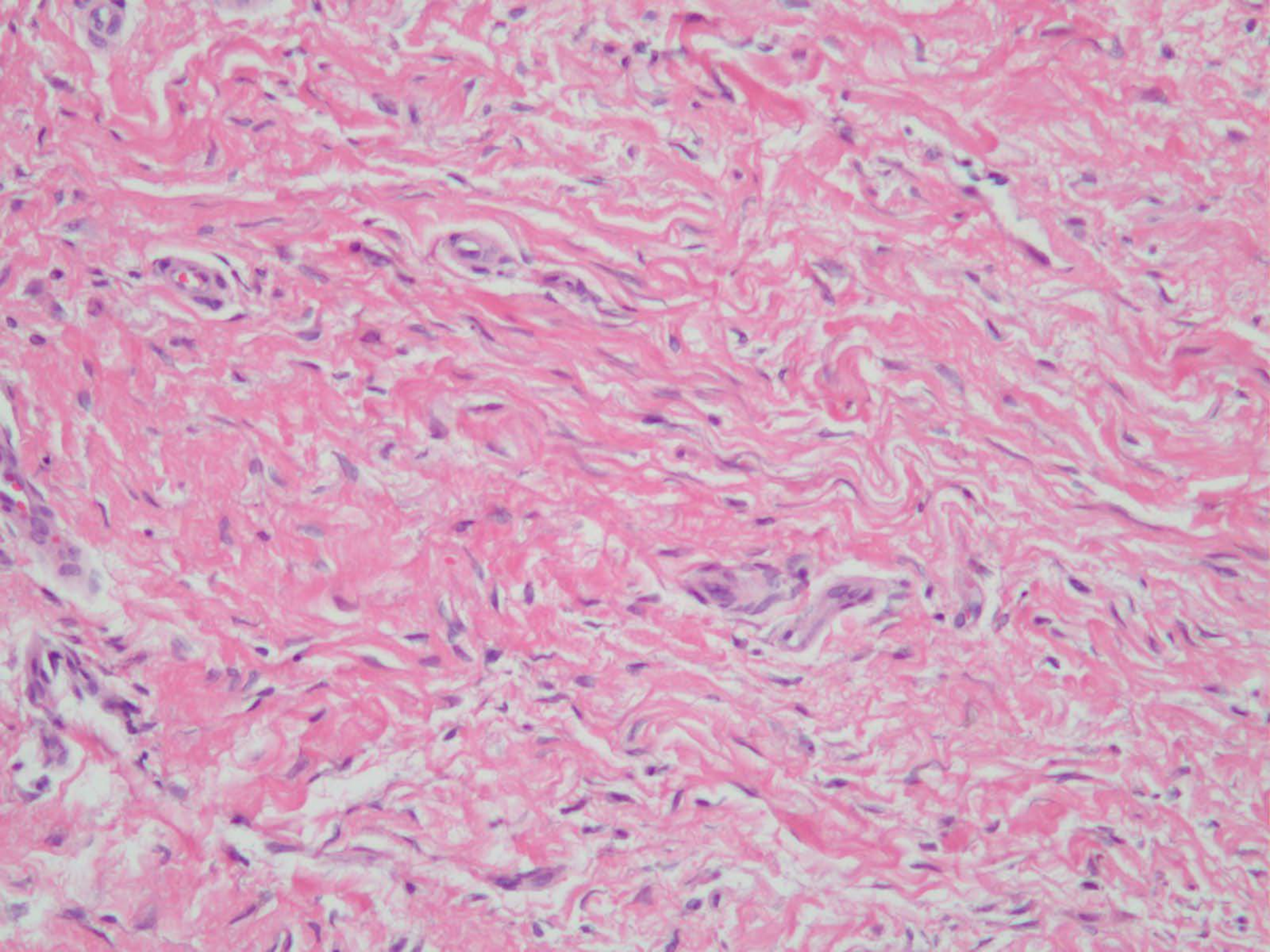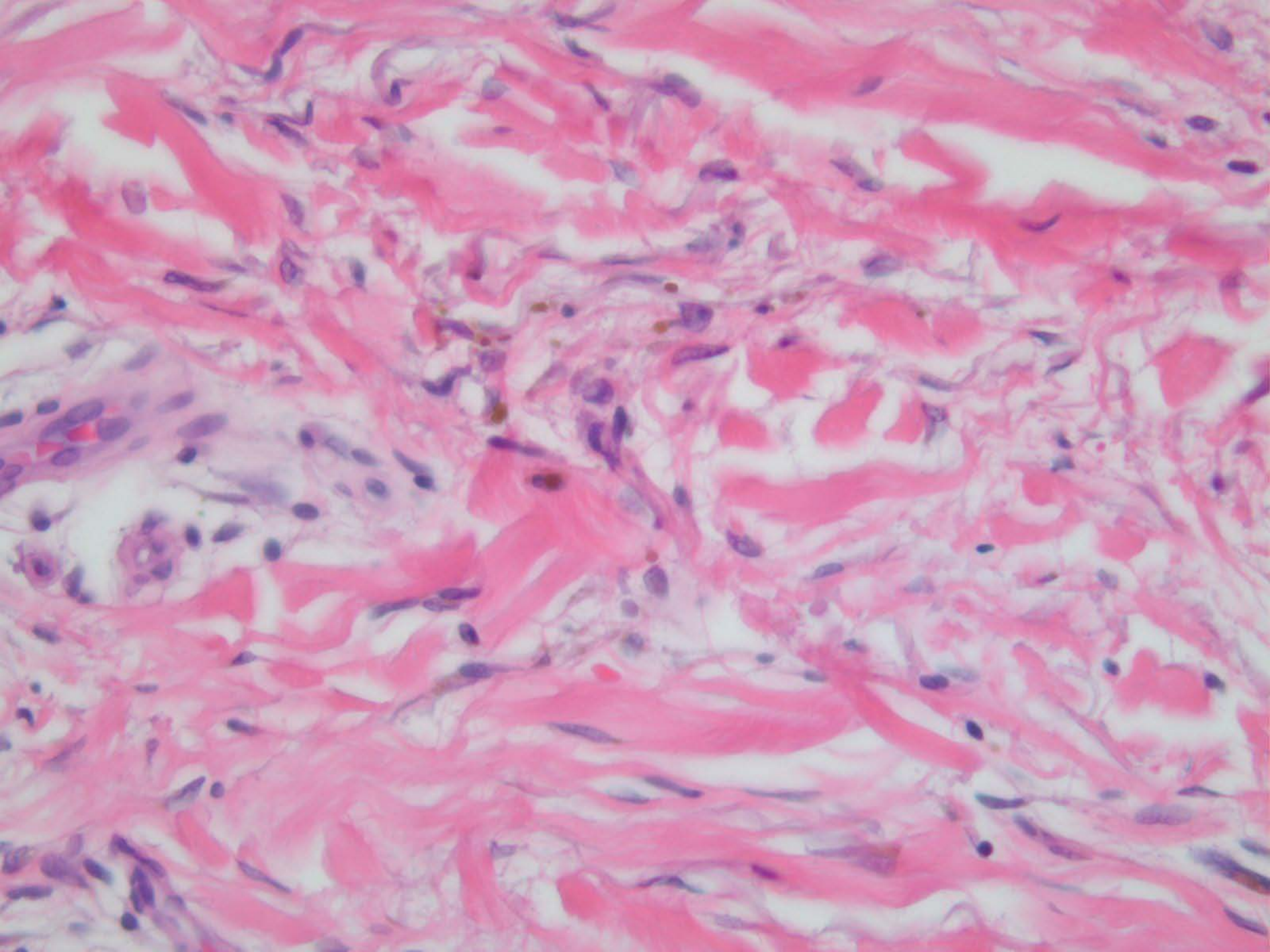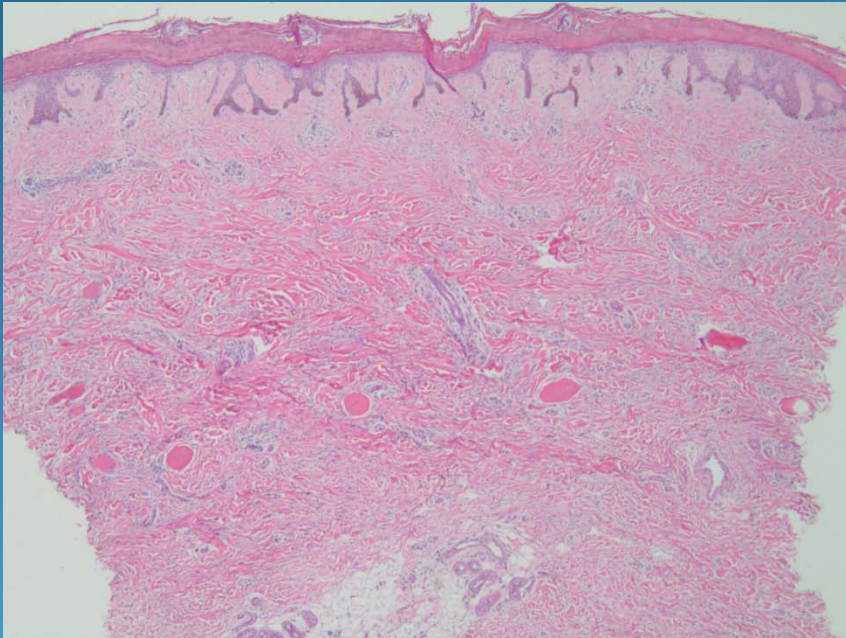


Nephrogenic Systemic Fibrosis (Nephrogenic Fibrosing Dermopathy)

Pearls



- Square biopsy sign with diffuse dermal fibrosis
- No atypia of fibroblasts
- May have increase in mucin ground substance
- Fibroblasts positive for F. XIIIa and CD34
- DDX: Morphea, Scleromyxedema